

# Desquamative Interstitial Pneumonia: A Case Report

Aleksandra Lovrenski<sup>1</sup>, Živka Eri<sup>1</sup>, Dragana Tegeltija<sup>1</sup>, Svetlana Kašiković-Lečić<sup>2</sup>, Milana Panjković<sup>1</sup>

<sup>1</sup>Center for Pathology, Institute for Pulmonary Diseases of Vojvodina, Sremska Kamenica, Serbia;

<sup>2</sup>Clinic for Tuberculosis and Granulomatous Diseases, Institute for Pulmonary Diseases of Vojvodina, Sremska Kamenica, Serbia

## SUMMARY

**Introduction** Desquamative interstitial pneumonia is one of the rarest idiopathic interstitial pneumonias and the rarest form of smoking-related interstitial lung diseases. It was first described by Liebow in 1965. Histologically, it is characterized by the presence of eosinophilic macrophages uniformly filling airspaces which often contain a finely granular light-brown pigment that does not stain for hemosiderin. The alveolar walls are usually mildly thickened by fibrous tissue and infiltrated by a moderate number of lymphocytes.

**Case Outline** Our patient was a 56-year-old male, heavy smoker, with bilateral lung infiltrations of unknown etiology and several months of discomfort in the form of dry cough and shortness of breath. Lung function tests showed a moderate restrictive ventilation disorder and a severe reduction of diffusing capacity. Since bronchoscopic specimens did not reveal lung lesion etiology, an open lung biopsy of the lower left pulmonary lobe was performed, and based on the obtained surgical material the pathohistologically diagnosis of desquamative interstitial pneumonia was established. The patient was started on corticosteroid and immunosuppressive therapy, and he ceased smoking. At the last control examination, two years after the onset of symptoms, the patient was feeling well, and high-resolution computed tomography (HRCT) scan of the thorax showed regression of pathological changes.

**Conclusion** Although, as in our case, the majority of DIP patients improve on treatment, some patients still develop progressive irreversible fibrosis despite therapy.

**Keywords:** desquamative interstitial pneumonia; interstitial lung disease; smoking; smokers; macrophages; smoking-related interstitial lung disease

## INTRODUCTION

Desquamative interstitial pneumonia (DIP) is one of the rarest idiopathic interstitial pneumonias. Together with respiratory bronchiolitis-interstitial lung disease (RB-ILD) and Langerhans cell histiocytosis it can be a part of smoking related interstitial lung diseases (SR-ILD) [1]. It is characterized by the accumulation of macrophages in large numbers in the alveolar spaces associated with interstitial inflammation with or without fibrosis. The alveolar macrophages frequently contain a light brown pigment which does not stain for hemosiderin, and because of their association with smoking they are called smoker's macrophages. Lymphocytic infiltrate within the alveolar septa, often in the form of lymphoid nodules are common [1, 2]. Most cases of DIP are caused by cigarette smoking, but drugs (especially marijuana smoke) and other inhaled agents can also produce the same disease. Although the majority of DIP patients improve on treatment, some patients develop progressive irreversible fibrosis [2, 3].

cough and shortness of breath, fever and loss of body weight was admitted to hospital in May 2011. On physical examination digital clubbing and bilateral basal inspiratory crackles were present. Laboratory findings showed moderately elevated markers of inflammation (SE 80 mm/h, WBC  $11.9 \times 10^9/L$ , fibrinogen 5 g/l). Lung test function revealed a moderately restrictive ventilation disorder (FVC 2.87 (68.8% predicted), TLC 5.4 (80% predicted)) and severe reduction of diffusion capacity (DLCO<sub>SB</sub> 2.51 (26.4% predicted)). Arterial blood gas analysis showed manifest partial respiratory insufficiency (PaO<sub>2</sub> 7.98, kPa, PaCO<sub>2</sub> 5.34, SaO<sub>2</sub> 91.6%). PaO<sub>2</sub> dropped to 6.21 and kPa at minimal exertion (walking on a flat surface for 6 minutes).

On CT scan of the thorax, bilateral areas of ground glass opacification, more pronounced dorsally were described (Figure 1). After first bronchoscopy, the etiology of lesions remained unknown. After second bronchoscopy, in material obtained by transbronchial biopsy, areas of organizing pneumonia were revealed. Since this feature was nonspecific lung biopsy was performed.

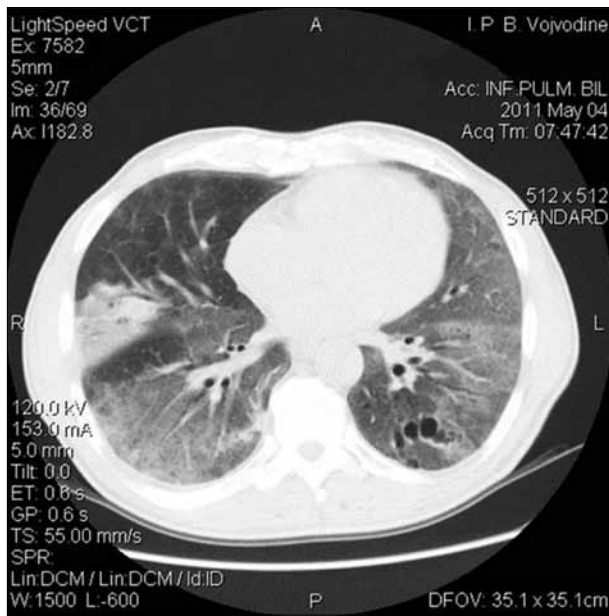
Grossly, a resected specimen of the lower left pulmonary lobe taken during open lung biopsy procedure, 4×2 cm in dimensions, showed mildly thickened, blurred pleura. On cross section, the lung parenchyma was dark-grey with reduced airiness (Figure 2).

## CASE REPORT

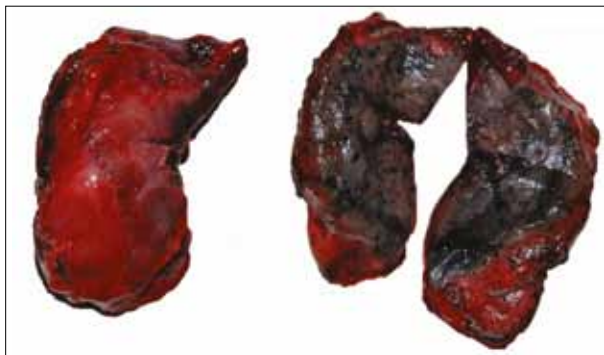A 56-year-old male patient, a painter, heavy smoker (2 packs per day/40 years), with several months of discomfort in the form of dry

### Correspondence to:

Aleksandra LOVRENSKI  
Center for Pathology  
Institute for Pulmonary Diseases  
of Vojvodina  
Put doktora Goldmana 4  
21204 Sremska Kamenica  
Serbia  
ajalovrenski@yahoo.com

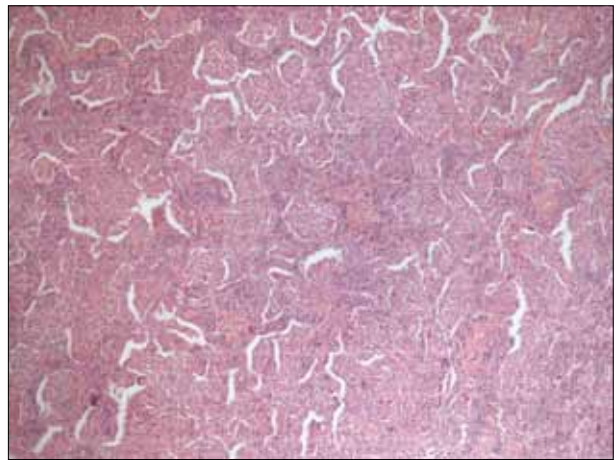


**Figure 1.** CT scan of the thorax: bilateral areas of ground glass opacification, more pronounced dorsally

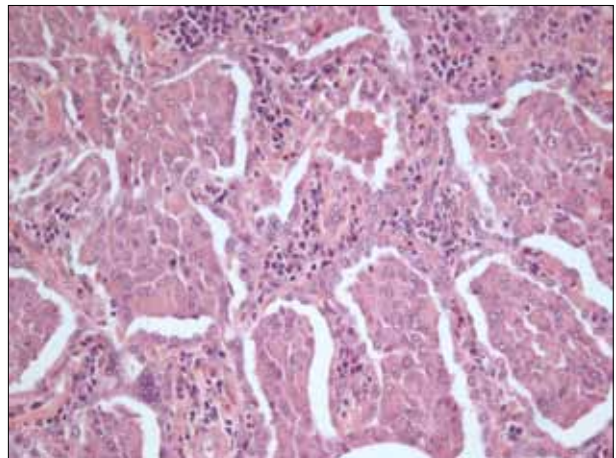


**Figure 2.** Grossly, the lung tissue shows mildly thickened, blurred pleura, and on cross section parenchyma is dark-grey with reduced airiness

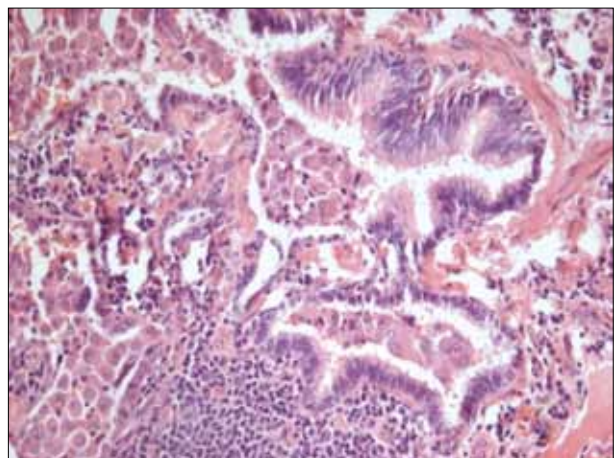
The operative material was entirely histologically examined. The histological sections were stained by the routine hematoxyline-eosin (HE) method and Perls Prussian Blue. On scanning magnification, the lung parenchyma had eosinophilic appearance due to the presence of a large number of eosinophilic macrophages uniformly filling airspaces (Figure 3). The macrophages had abundant eosinophilic cytoplasm, which often contained a finely granular light brown pigment. On Perls Prussian blue stain, this pigment within the cytoplasm of macrophages did not stain for hemosiderin as common in heavy smokers (smokers' macrophages). Alveolar walls were mildly thickened by fibrous tissue uniform in appearance and infiltrated by a moderate number of lymphocytes, scant numbers of plasma cells and rare eosinophils (Figure 4). Focally, within the alveoli a moderate numbers of multinucleated macrophages were present. Macrophages were also present within the lumen of bronchioles whose walls were focally infiltrated with lymphocytes forming a respiratory bronchiolitis-like feature (Figure 5). Focally, chronic inflammation was evident in the form of lymphoid follicles which were associated with respiratory bronchioles. The



**Figure 3.** On scanning magnification, lung parenchyma shows eosinophilic appearance due to the presence of a large number of eosinophilic macrophages uniformly filling airspaces (H&E, x50).



**Figure 4.** Macrophages with abundant eosinophilic cytoplasm, which often contain a finely granular light brown pigment. Alveolar walls are mildly thickened by fibrous tissue uniform in appearance and infiltrated by a moderate number of lymphocytes (H&E, x200).



**Figure 5.** Respiratory bronchiolitis-like picture: macrophages present within lumen of bronchioles whose walls are focally infiltrated with lymphocytes (H&E, x200)

pleura showed slight thickening, and it was infiltrated with lymphocytes, plasma cells and rare eosinophils. Based on such microscopic findings, our diagnosis was DIP.

Immediately after diagnosis, the patient was introduced to oral corticosteroid therapy (prednisone 60 mg per day)

and azathioprine (150 mg per day), as well as smoking cessation and ceased working in order to avoid further exposure to inhaled agents. The patient was released from hospital with regular follow-ups at our Institute. After six months of combined medicamentose therapy, azathioprine was excluded, and the treatment was carried on with low doses of oral corticosteroids within the next three months. In view of significant improvement at the follow-up and high-resolution computed tomography (HRCT) scan findings, after 9-month therapy in terms of reduction of active changes within the lung, further treatment was ceased. The patient was still under pulmonologist's supervision. A year without treatment, the patient has been asymptomatic regarding the respiratory system, with a mild reduction of single-breath carbon-monoxide diffusing capacity of the lungs (DLCO<sub>SB</sub> 43% predicted) and without restrictive ventilation disorder. HRCT scan a year after the beginning of treatment revealed unchanged findings compared to the previous one.

## DISCUSSION

Desquamative interstitial pneumonia (DIP) is an uncommon form of interstitial lung disease of unknown etiology. This entity, first described by Liebow in 1965, is characterized by diffuse interstitial infiltrates on chest roentgenogram, restrictive pulmonary function tests, and histology which demonstrates intraalveolar accumulation of macrophages [4].

According to Tazelaar et al. [2], approximately 90% of patients with DIP are smokers. On the other hand, in the series of Craig et al. [5] 40% of 20 patients were lifelong nonsmokers, and in an older series of Tubbs et al. [6] 42% of 26 patients had no history of cigarette smoking. These findings suggest that DIP can occasionally be seen in nonsmokers in association with infections, and exposure to occupational or environmental agents or drugs, including marijuana smoke [7]. Abraham and Hertzberg [8] explored biopsies of inorganic particles by scanning electron microscopy of 62 pathohistologically-proven cases of DIP. They found inorganic particles in 17 patients; of these, seven had an occupational history compatible with exposure to inorganic particles, and high concentrations of inorganic particles in biopsy samples. Also, Moon et al. [9] described a case of DIP in a nonsmoking patient who was exposed to solder fumes at work. Craig et al. [5] showed that among 20 patients, two of eight nonsmokers and one patient in the smoker group, were exposed to occupational dust as fire-extinguisher powder, diesel fumes, and beryllium and copper dust, respectively. Lougheed et al. [10] described a series of five textile workers who were exposed to nylon filaments; two of these were ex-smokers and three never smoked. The reported cases of recurrent DIP following lung transplantation suggest a systemic pathogenesis of DIP. The relapse of this disease in a patient with lung transplant suggests that in certain individuals DIP represents a pulmonary manifestation of a systemic disease [11, 12].

Clinically, patients, most commonly middle age cigarette smokers, present with symptoms of dyspnea and nonproductive cough. Males are affected nearly twice as often as females [1, 2]. Physical examination demonstrates inspiratory crackles in 60% of patients and digital clubbing occurs in nearly one-half of patients. Pulmonary function testing reveals a predominantly restrictive defect, with reductions of 50% or more in diffusing capacity, with symmetrical reduction in lung volumes [13].

Chest radiographs are insensitive for detection of DIP and are reported to be normal in 3–22% of biopsy-proved cases. HRCT scan is sensitive for the detection and characterization of interstitial lung diseases and may allow recognition and classification of the SR-ILD into distinct individual entities. HRCT findings of DIP show ground-glass opacity, which may be peripheral, patchy, or diffuse in distribution. A peripheral subpleural and basal predominance of ground-glass opacity is most commonly seen [14].

Since the most significant histologic feature of DIP is intraalveolar accumulation of pigmented macrophages and not desquamated epithelial cells as previously thought, the term “desquamative” is a misnomer [2, 5]. Major features necessary to set diagnosis of DIP are: uniform involvement of lung parenchyma, marked accumulation of macrophages and light brown cytoplasmic pigmentation within macrophages. Minor (or secondary) features are: mild to moderate interstitial fibrosis, mild interstitial chronic inflammation, mild follicular hyperplasia and often a mildly increased numbers of eosinophils. The overall alveolar architecture is usually well maintained, and honeycombing is minimal or absent, as well as fibroblastic foci (typical features of usual interstitial pneumonia – UIP) [2, 5].

However, clinical, radiologic, and histological features overlap among different SR-ILDs, and mixed patterns of the disease frequently coexist in the same patient [13]. The overlap is most significant between RB-ILD and DIP. Although RB-ILD is a closely related process, there are prognostic reasons for continuing to separate it from DIP when possible. RB-ILD most often presents between the third and sixth decades with dyspnea, persistent cough, while chest pain and weight loss are less frequent. Bilateral, predominantly basal inspiratory crackles are common, but clubbing is very rare. Patients with DIP are generally older than patients with RB-ILD, present in the fourth to sixth decade also with dyspnea, non-productive cough and, less frequently, fatigue and weight loss. Bilateral basal inspiratory crackles are frequent, and clubbing is more often present than in patients with RB-ILD. In RB-ILD, both restrictive and obstructive abnormalities have been documented, while in DIP the ventilatory defect is consistently restrictive [15]. The key feature to differentiate the two disorders is histological finding. The distribution and extent of the lesions within the lung parenchyma are crucial for the exact diagnosis; macrophage accumulation is bronchiolocentric in RB-ILD producing centrilobular ground-glass opacity, and more diffuse in DIP producing widespread ground-glass changes [16]. Also, it is very important to emphasize that DIP is usually a more aggressive process than RB-ILD

with no evidence that RB-ILD progresses to DIP [12]. Treatment (initially with corticosteroid therapy) is generally necessary in DIP but is rarely needed in RB-ILD, especially if smoking cessation is achieved [16]. The final diagnosis of SR-ILD and identification of the specific entity can be achieved only in cooperation with the clinician, the radiologist, and finally the pathologist.

Smoking cessation has the prime role in the treatment of DIP and may lead to disease regression [2]. Also, the cessation of exposure is necessary. In the series of five patients studied by Loughheed et al. [10] two patients improved upon leaving the workplace and did not require steroid therapy, while two of the five patients returned to work and both experienced a relapse. Most patients show good response to oral corticosteroids and immunosuppressive therapy. With such treatment, most patients remain stable or improve, and complete recovery is possible [17, 18]. In contrast, Aubry et al. [1] showed that response

to corticosteroids is not uniform as approximately 25% of patients may continue to progress despite treatment. According to Kawabata et al. [3], corticosteroid therapy was effective early in the course of the disease, and long-term follow-up (mean 99 months) of 31 patients showed only one death due to the progression of the disease, but a long-term follow-up of 14 patients (mean 125 months) five developed fibrosis and four lung cancer detected by HRCT scan, respectively. In a series of five patients, Knyazhitskiy et al. [19] suggest a possible role for macrolide antibiotics in patients with DIP refractory to steroid therapy. They described the first case of DIP showing a rapid and dramatic response to treatment with clarithromycin.

Patients with DIP are thought to have a more favorable prognosis than other forms of idiopathic pulmonary fibrosis; however patients can progress to end stage disease, and may require lung transplantation as definitive treatment [16]. The 10-year survival rates are 70% [20].

## REFERENCES

1. Aubry MC, Wright JL, Myers JL. The pathology of smoking-related lung disease. *Clin Chest Med.* 2000; 21(1):11-35.
2. Tazelaar HD, Wright JL, Churg A. Desquamative interstitial pneumonia. *Histopathology.* 2011; 58(4):509-16.
3. Kawabata Y, Takemura T, Hebisawa A, Sugita Y, Ogura T, Nagai S, et al. Desquamative interstitial pneumonia may progress to lung fibrosis as characterized radiologically. *Respirology.* 2012; 17(8):1214-21.
4. Liebow AA, Steer A, Billingsley JG. Desquamative interstitial pneumonia. *Am J Med.* 1965; 39:369-404.
5. Craig PJ, Wells AU, Doffman S, Rassel D, Colby TV, Hansell DM, et al. Desquamative interstitial pneumonia, respiratory bronchiolitis and their relationship to smoking. *Histopathology.* 2004; 45(3):275-82.
6. Tubbs RR, Benjamin SP, Reich NE, McCormack LJ, Van Ordstrand HS. Desquamative interstitial pneumonitis. Cellular phase of fibrosing alveolitis. *Chest.* 1977; 72:159-65.
7. Godbert B, Wissler MP, Vignaud JM. Desquamative interstitial pneumonia: an analytic review with an emphasis on aetiology. *Eur Respir Rev.* 2013; 22(128):117-23.
8. Abraham JL, Hertzberg MA. Inorganic particles associated with desquamative interstitial pneumonia. *Chest.* 1981; 80:67-70.
9. Moon J, Du Bois RM, Colby TV, Hansell DM, Nicholson AG. Clinical significance of respiratory bronchiolitis on open lung biopsy and its relationship to smoking-related interstitial lung disease. *Thorax.* 1999; 54:1009-14.
10. Loughheed MD, Roos JO, Waddell WR, Munt PW. Desquamative interstitial pneumonitis and diffuse alveolar damage in textile workers. Potential role of mycotoxins. *Chest.* 1995; 108:1196-200.
11. King M, Jessurun J, Hertz M. Recurrence of desquamative interstitial pneumonia after lung transplantation. *Am J Respir Crit Care Med.* 1997; 156(6):2003-5.
12. Verleden GM. Recurrence of desquamative interstitial pneumonia after lung transplantation. *Am J Respir Crit Care Med.* 1998; 157(4):1349-50.
13. Selman M. The spectrum of smoking-related interstitial lung disorders: the never-ending story of smoke and disease. *Chest.* 2003; 124(4):1185-7.
14. Attili AK, Kazerooni EA, Gross BH, Flaherty KR, Myers JL, Martinez FJ. Smoking-related interstitial lung disease: radiologic-clinical-pathologic correlation. *RadioGraphics.* 2008; 28(5):1383-96.
15. Ryu JH, Myers JL, Capizzi SA, Douglas WW, Vassallo R, Decker PA. Desquamative interstitial pneumonia and respiratory bronchiolitis-associated interstitial lung disease. *Chest.* 2005; 127(1):178-84.
16. Katzenstein AL. Smoking-related interstitial fibrosis (SRIF), pathogenesis and treatment of usual interstitial pneumonia (UIP), and transbronchial biopsy in UIP. *Modern Pathology.* 2012; 25:68-78.
17. Yousem SA, Colby TV, Gaensler EA. Respiratory bronchiolitis-associated interstitial lung disease and its relationship to desquamative interstitial pneumonia. *Mayo Clin Proc.* 1989; 64:1373-80.
18. Hartman TE, Primack SL, Kang EY, Swensen SJ, Hansell DM, McGuinness G, et al. Disease progression in usual interstitial pneumonia: assessment with serial CT. *Chest.* 1996; 110:378-82.
19. Knyazhitskiy A, Masson RG, Corkey R, Joiner J. Beneficial response to macrolide antibiotic in a patient with desquamative interstitial pneumonia refractory to corticosteroid therapy. *Chest.* 2008; 134:185-7.
20. Katzenstein AL, Myers J. Idiopathic pulmonary fibrosis. *Am J Respir Crit Care Med.* 1998; 157(4):1301-15.

## Десквамативна интерстицијална пнеумонија – приказ болесника

Александра Ловренски<sup>1</sup>, Живка Ери<sup>1</sup>, Драгана Тегелтија<sup>1</sup>, Светлана Кашиковић-Лечић<sup>2</sup>, Милана Пањковић<sup>1</sup>

<sup>1</sup>Центар за патологију, Институт за плућне болести Војводине, Сремска Каменица, Србија;

<sup>2</sup>Клиника за туберкулозу и грануломатозне болести, Институт за плућне болести Војводине, Сремска Каменица, Србија

### КРАТАК САДРЖАЈ

**Увод** Десквамативна интерстицијална пнеумонија је једна од најређих интерстицијалних болести плућа и најређи облик интерстицијалних болести плућа удружених с пушењем. Први пут су је описали 1965. године Либов (*Liebow*) и сарадници. Хистолошки се одликује постојањем еозинофилних макрофага унутар алвеоларних простора који често садрже фино гранулиран, светлосмеђ пигмент који се не боји на хемосидерин. Зидови алвеола су умерено задебљани услед умножавања везивног ткива и инфилтровани средње густим инфилтратом лимфоцита.

**Приказ болесника** Наш болесник је 56-годишњи мушкарац, дугогодишњи пушач, с обостраним плућним инфилтратима непознате етиологије и вишемесечним тегобама у виду сувог кашља и диспнеје. Тестови плућне функције открили су умерен рестриктивни поремећај вентилације и тешко смањење капацитета дифузије. Како бронхоскопска

испитивања нису разјаснила порекло промена у плућима, извршена је отворена биопсија доњег левог режња и на основу добијеног материјала патохистолошки је постављена дијагноза десквамативне интерстицијалне пнеумоније. Болеснику је забрањено пушење и преписана му је кортикостероидна и иминосупресивна терапија. На последњем контролном прегледу, две године након појаве симптома, болесник се добро осећао, а високорезолуцијска компјутеризована томографија грудног коша показала је повлачење промена у плућима.

**Закључак** Иако се, као у приказаном случају, већина болесника опорави након лечења, код неких болесника се, упркос терапији, ипак развије прогресивна ирверзибилна фиброза.

**Кључне речи:** десквамативна интерстицијална пнеумонија; интерстицијална болест плућа; пушење; пушачки макрофаги; интерстицијална болест плућа удружена с пушењем

Примљен • Received: 21/10/2013

Прихваћен • Accepted: 16/12/2013