

Cervical Epidural Hematoma: Case Report

Vesna Novak¹, Ivan Stefanović¹, Aleksandar Kostić¹, Miša Radisavljević¹, Martin Novak², Boban Jelenković¹, Luka Berilažić¹

¹Clinic of Neurosurgery, Clinical Centre, Niš, Serbia;

²Children's Clinic of Internal Diseases, Clinical Centre, Niš, Serbia

SUMMARY

Introduction Cervical epidural hematoma is a rare phenomenon in children. MRI scan of the cervical spine is the method of choice in establishing diagnosis and a quick evacuation of hematoma and decompression.

Case Outline We present a case of 11-year-old boy whose lower extremities were paralysed after a trivial injury of the cervical spine which he sustained while playing. Seven days after the injury, severe clinical symptoms appeared, and MRI of the spine showed the presence of cervical epidural hematoma.

Conclusion Cervical epidural hematoma in children is very rare. Adequate neurological examination, diagnostics and urgent surgical intervention are of paramount importance for accomplishing good results. Early and persistent rehabilitation are the condition for achieving maximal recovery.

Keywords: epidural haematoma; cervical spine; paraplegia

INTRODUCTION

Cervical epidural hematoma is a rare phenomenon in children. It was first described by Jackson [1] as early as in 1963. A trivial injury involving a sprain of the cervical spine without any lesions on bone structures can sometimes cause a serious damage of the neurovascular elements.

MRI scan of the cervical spine is the method of choice in establishing the diagnosis and a quick evacuation of hematoma and the decompression have proven to be the principal methods of treatment which provide satisfying results [2, 3].

CASE REPORT

An 11-year-old child was admitted at the Child Neurology Clinic on 7th March 2011 due to neck pain, headache, vomiting and inability to walk. A week before admission he suffered a neck injury while playing (his friend sprained his neck in the so-called headlock). He visited the doctor because of neck pain when X-ray of the cervical spine was done, which showed no signs of traumatic lesion. Wearing a cervical collar was recommended. A week later he developed a severe headache followed by vomiting and weakness in the lower extremities with dysfunction of the sphincter. The patient was examined by a general practitioner and referred to a pediatric neurologist. He was hospitalized at the Child Neurology Clinic; MRI of the cervical spine which was done immediately revealed the presence of epidural hematoma spanning C5 to TH3 (Figure 1). The neurologic status of the child was declining.

Following a consultation with a neurosurgeon, the child was transferred to the Neurosurgery Clinic. On admission, besides the flaccid paraplegia of the lower extremities, the patient felt weakness of the arms and had difficulty breathing, so that he was immediately intubated and underwent surgery on the same day, 7th March 2011. Laminectomy spanning from C7 to TH1 was performed intraoperatively and the epidural hematoma was evacuated. Postoperatively, breathing soon stabilized so that the child was extubated. He regained consciousness and was eupneic. The general motoric strength of the arms was preserved with the loss of fine finger movements, and the flaccid paraplegia of the lower extremities remained. Evoked potentials of the 8th March 2011 for the upper extremities showed regular cortical responses on both sides with regular latency, whereas the cortical responses of both lower extremities were absent. The results of control MRI of the cervical spine (Figure 2) performed on the 10th March 2011 revealed the presence of medullary edema with minimal epidural bleeding. Physical therapy was introduced. Evoked potentials of the 14th March 2011 showed very low amplitude responses of the lower extremities. The surgical wound healed per primam; sutures were removed on the postoperative day 8. Prior to discharge, X-ray of the lungs and ECHO of the abdomen were done; both findings were within normal limits. A urinary catheter was clipped and the child was started with bladder training. On the 22nd March 2011, the patient was transferred to the Clinic of Physical Medicine and Rehabilitation in Niš for further treatment. Neurological status of December 2011: sphincter control. Movements of hands possible, lacking fine movements of the distal

Correspondence to:

Vesna NOVAK
Clinic of Neurosurgery
Clinical Center Niš
Bulevar dr Zorana Đinđića 48
18000 Niš
Serbia
v.novak@yahoo.com

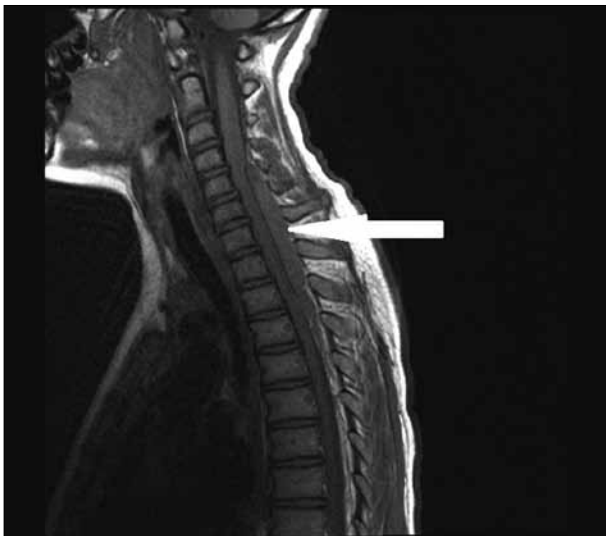


Figure 1. Preoperative MRI of cervical spine, epidural hematoma C5-Th3

phalanx. In the lower extremities present hyperesthesia and paresthesia. Possible withdrawal of the lower limbs in bed.

Neurological status of June 2012: possible fine finger movements, achieved verticalization and walk with the support of orthotics.

DISCUSSION

Cervical epidural hematoma is quite rare in children with incidence of 0.1 per 100 [4]. It is usually caused by trivial neck injuries such as neck sprain due to hanging on a pole [5], injury sustained in a traffic accident or after falling from height [6]. During the examination immediately after the injury, there is usually only tenderness in the neck region, while X-ray of the cervical spine shows no lesions. Torticollis [3], paresthesia, focal neurological deficit, Brown-Sequard syndrome [7] are symptoms which indicate that urgent clinical and diagnostic observation is necessary. CT scan of the cervical spine must be done as soon as possible [8] although the most precise diagnosis can be made by MRI [9]. The problem in this case was the fact that the child came from a village, where X-ray imaging was the only diagnostic tool available. Only when a complete paralysis of the lower limbs with the sphincter dysfunction set in was the child referred to a larger medical centre for examination by a neurologist. With the appearance of neurological deficits, the clinical status and worsening of the symptoms in patients with epidural cervical hematoma are foudroyant. The time elapsed between the moment of injury and the surgical evacuation of hematoma is the most important factor for achieving good

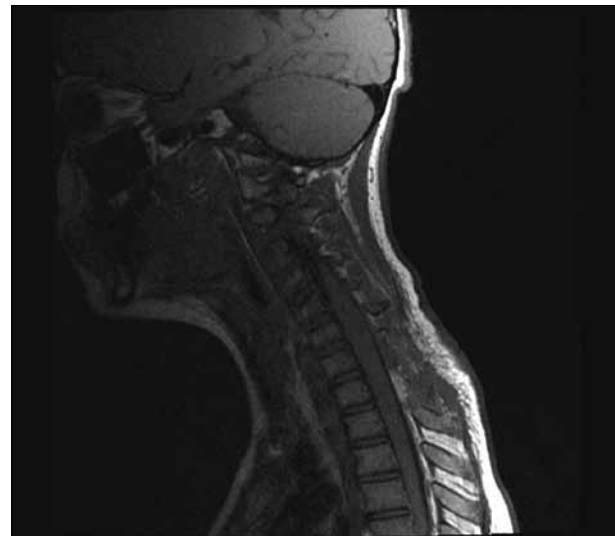


Figure 2. Postoperative MRI of the cervical spine

results [10, 11]. If the pre-operative neurological deficit lasts for a long time, it is unlikely that it will disappear after decompression.

It is necessary to evacuate the hematoma as soon as possible and to decompress. The clinical status and the size of hematoma determine the extent of the surgical procedure, i.e. whether hemilaminectomy or laminectomy will be performed with the evacuation of hematoma [2, 12, 13]. In our case, the greatest width of hematoma was the level C7 to Th2. Surgical technique implied central positioning of the operative field and keeping the lamina within marginal positions. Epidural hematoma allows the possibility of applying fine-catheter (2-3 cm) aspirations from the downloaded lamina. Thus, further destabilization of the spine can be avoided. The possibility of the hematoma being drained by the removal of lamina C5 and Th3 and aspiration was not probable because of the consistency of hematoma. As such cases are quite rare, our experience is low, so that at the time the decision was made to apply laminectomy of C7 to Th1, without considering plastic. A wider laminectomy and decompression were more desirable since the medullary edema appeared after the removal of hematoma. Following the operation, the patient was breathing normally and the upper extremities were functioning, while there was still paraplegia of the lower extremities with the lack of sphincter control. What is essential for accomplishing satisfying results with cervical epidural hematomas is to promptly reach the diagnosis and perform surgery. Iguchi et al. [10] presented a series of 13 patients with cervical epidural hematoma with excellent recovery in 61.5% of the cases, solid in 23.1% and poor in 15.4%. Early postoperative rehabilitation is also vital for achieving better results [14].

REFERENCES

- Jackson FE. Spontaneous spinal epidural hematoma coincident with whooping cough. Case report. *J Neurosurg.* 1969; 20:715-7.
- Alva NS. Traumatic spinal epidural hematoma of a 10-month-old male: a clinical note. *Pediatr Neurol.* 2000; 23:88-9.
- Kirwan R, Saigal G, Faingold R, O'Gorman A. Nontraumatic acute and subacute enhancing spinal epidural hematoma mimicking a tumor in a child. *Pediatr Radiol.* 2004; 34:499-502.
- Fountas KN, Kapsalaki EZ, Robinson JS. Cervical epidural hematoma in children: a rare clinical entity. *Neurosurg Focus.* 2006; 20(2):E6.
- Ghanem Q, Ivan LP. Spontaneous spinal epidural hematoma in an 8-year-old boy. *Neurology.* 1978; 28:829-32.
- Nagel MA, Taff IP, Cantos EL, Patel MP, Maytal J, Berman D. Spontaneous spinal epidural hematoma in a 7-year-old girl. Diagnostic value of magnetic resonance imaging. *Clin Neurol Neurosurg.* 1989; 91:157-60.
- Russman BS, Kazi KH. Spinal epidural hematoma and the Brown-Sequard syndrome. *Neurology.* 1971; 21:1066-8.
- Terae S, Kudo K, Asano T, Ushikoshi S, Hida K, Iwasaki Y, et al. CT angiography with multisection helical CT in spinal arteriovenous malformation. *Clin Imaging.* 2004; 28:23-7.
- Bejjani GK, Donahue DJ, Rusin J, Broemeling LD. Radiological and clinical criteria for the management of epidural hematomas in children. *Pediatr Neurosurg.* 1996; 125(6):302-8.
- Iguchi T, Ito Y, Asai M, Ito J, Okada N, Murakami M. A case of spontaneous spinal epidural hematoma. *No To Hattatsu.* 1993; 25:267-70.
- Tender GC, Awasthi D. Spontaneous cervical spinal epidural haematoma in a 12-year-old girl: case report and review of the literature. *J La State Med Soc.* 2004; 156:196-8.
- Yasuoka S, Peterson HA, Laws ER Jr, MacCarty CS. Pathogenesis and prophylaxis of postlaminectomy deformity of the spine after multiple level laminectomy: difference between children and adults. *Neurosurgery.* 1981; 9:145-52.
- Yasuoka S, Peterson HA, MacCarty CS. Incidence of spinal column deformity after multilevel laminectomy in children and adults. *J Neurosurg.* 1982; 57:441-5.
- Bennett DL, George MJ, Ohashi K, El-Khoury GY, Lucas JJ, Peterson MC. Acute traumatic spinal epidural hematoma: imaging and neurologic outcome. *Emerg Radiol.* 2005; 11:136-44.

Цервикални епидурални хематом – приказ болесника

Весна Новак¹, Иван Стефановић¹, Александар Костић¹, Миша Радисављевић¹, Мартин Новак²,
Бобан Јеленковић¹, Лука Берилажић¹

¹Клиника за неурохирургију, Клинички центар, Ниш, Србија;

²Клиника за дечје интерне болести, Клинички центар, Ниш, Србија

КРАТАК САДРЖАЈ

Увод Цервикални епидурални хематом се ретко јавља код деце. Магнетна резонанција (МР) вратне кичме је метода избора у дијагностиковању овог стања која уједно омогућава и брзу евакуацију хематома и декомпресију.

Приказ болесника Једанаестогодишњи дечак је након баналне повреде вратне кичме у игри остао с одузетошћу доњих екстремитета. Седам дана након повређивања дошло је до интензивног испољавања клиничких симптома, а начи-

њена МР вратне кичме открила је постојање цервикалног епидуралног хематома.

Закључак Цервикални епидурални хематом је редак у педијатријској популацији. Правилан неуролошки преглед, одговарајућа дијагностика и хитна хируршка интервенција су важни за постизање добрих резултата лечења. Рана и перманентна рехабилитација су услов за постизање максималног опоравка болесника.

Кључне речи: епидурални хематом; цервикална кичма; парализација

Примљен • Received: 08/10/2013

Прихваћен • Accepted: 03/12/2013