

# Pedunculated Obstructive Lipoma of the Ileocecal Valve: A Case Report

Berislav Vekić, Rastko Živić

Surgical Clinic, Clinical Center "Dr Dragiša Mišović" – Dedinje, Belgrade, Serbia

## SUMMARY

**Introduction** Colonic lipomas are relatively common but they rarely progress to complete acute obstruction.

**Case Outline** We report a case of a 67-year-old woman with acute intestinal obstruction caused by a large pedunculated lipoma of the ileocecal valve. Preoperatively, the patient presented acutely with clinical and radiographic signs of small intestine ileus. A right hemicolectomy with subsequent terminolateral ileocolostomy was performed. The histopathological examination revealed a benign lipoma of the ileocecal valve which telescoped into the cecum and caused ileocolonic intussusception. The postoperative course was uneventful and the patient was free of symptoms during a 12-month follow-up period.

**Conclusion** Since these benign tumors are frequently revealed by laparotomy and the definitive diagnosis is made on the basis of histopathological examination, we can conclude that extensive resections of the large intestine are justified in cases with acute clinical presentation.

**Keywords:** ileocecal lipoma; acute intestinal obstruction; colonic surgery; intussusception

## INTRODUCTION

Colonic lipomas are rare benign tumors, which constitute the most common nonepithelial (mesenchymal) neoplasm of the gastrointestinal tract [1, 2]. Ileocecal valve and cecum are most affected sites, followed by the rectum, sigmoid colon and descending colon [2]. They may be sessile or pedunculated. Although the majority are small and asymptomatic (<2 cm), the larger ones appear to correlate with symptomatology, such as abdominal pain, diarrhea, obstruction and rectal bleeding [3-6]. The first report of colonic lipoma was by Bauer in 1757 [7].

## CASE REPORT

A 67-year-old woman presented at the emergency room with a 3-day history of severe central abdominal pain, which was associated with nausea, vomiting, abdominal distention and complete constipation. She had a four-month history of change in bowel habits. On abdominal examination, she was found to have a distended and tender central abdomen, with tympanic percussion and silent bowel sounds, with no signs of peritonism. She had no previous abdominal operations. Rectal examination was unremarkable. Blood results were normal. Plain abdominal radiograph suggested a small intestine ileus. Since the patient did not respond to conservative therapy (tube decompression, enema) and considering the abdominal radiograph, mechanical bowel obstruction was obvious and immediate laparotomy was performed. Intraoperative findings revealed

dilatation of the whole small intestine caused by a palpable tumor mass in the ileocecal region with intussusception of the small intestine. A right hemicolectomy with subsequent termino-lateral ileocolostomy was performed. Macroscopic examination of the resected specimen showed a pedunculated, yellowish, soft tissue tumor of the ileocecal valve measuring 5 cm in diameter which telescoped into the cecum and caused ileocolonic intussusception (Figures 1 and 2). Subsequent histopathological examination revealed that the mass was a lipoma with no evidence of malignancy (Figure 3). The postoperative course was uneventful and she was discharged on postoperative day seven. The patient was free of symptoms during a 12-month follow-up period.

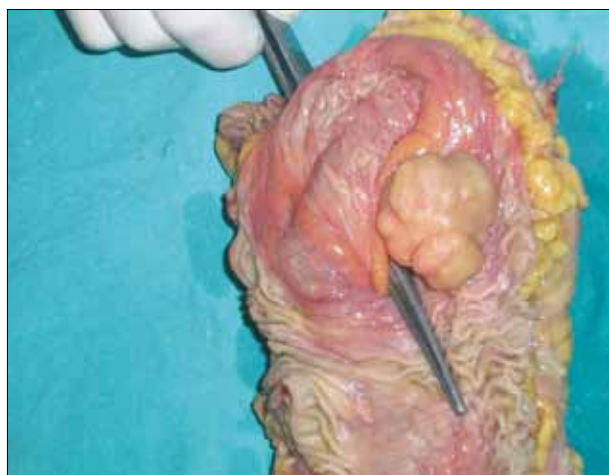## DISCUSSION

Colonic lipomas represent uncommon adipose neoplasms with a reported incidence ranging between 0.15 and 4.4% [8]. It is the third most common benign tumor of the large bowel after hyperplastic and adenomatous polyps [9]. These tumors are more prevalent in women than in men with a peak incidence in the 5<sup>th</sup> and 6<sup>th</sup> decade of life [2, 8, 10]. Most such lesions (65%) have been identified in the right colon [2, 10]. In 90% they are localized at the submucous level [2]. They may be sessile or pedunculated, usually solitary, but multiple lesions are also reported in 10 to 25% of cases [11]. No cases of malignant transformation or recurrent colonic lipoma have been reported [3].

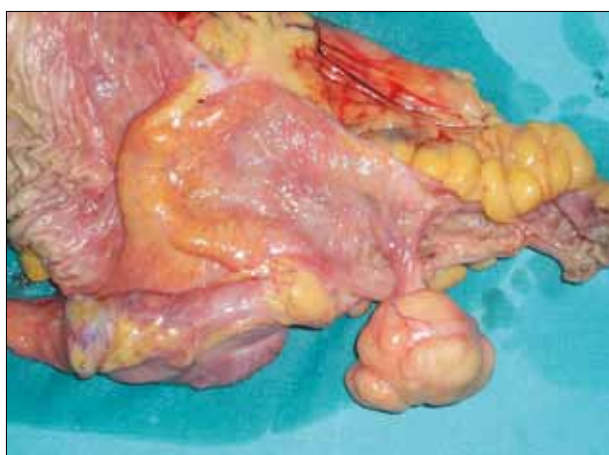Symptoms caused by colonic lipoma correlate with the size of the tumor. The majority

## Correspondence to:

Rastko ŽIVIĆ  
Vladimira Gaćinovića 32  
11000 Belgrade  
Serbia  
rale.zivic@gmail.com



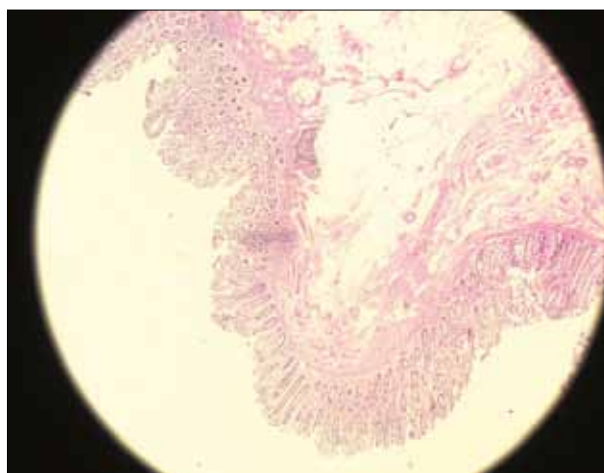
**Figure 1.** Gross finding of pedunculated lipoma of the ileocecal valve



**Figure 2.** Gross finding of bisected cecum with pedunculated lipoma of the ileocecal valve

is small and asymptomatic (<2 cm), and also suitable for endoscopic removal [3, 7, 8]. Large colonic lipomas are less suitable for endoscopic treatment considering the risks of complications, such as perforation and bleeding [7], but new endoscopic techniques are being developed to minimize such possibilities [12].

The majority of patients with lesions larger than 4 cm have the following symptoms: discomfort, abdominal pain and obstruction, which are mostly caused by chronic intermittent ileocolonic or colo-colonic intussusception or rectal bleeding as the result of atrophy and ulceration of mucosa overlying the lipoma [2-6, 8, 9, 10, 13].



**Figure 3.** Light microphotograph of lipoma of the ileocecal valve (H&E, original magnification x40)

Patients rarely present with dramatic clinical symptomatology necessitating urgent operative treatment, such as intussusception, which can lead to complete acute obstruction or acute hemorrhage. Franc-Law et al. [13] reported that the appearance of dramatic symptoms in colonic lipomas probably depends on the size of tumors and their position in the large intestine, and that larger tumors and rarer left-sided colonic lipomas are more likely to cause acute obstruction.

For large lipomas surgical resection is recommended to relieve symptoms or exclude malignancy [1, 8, 14], with a wide range of operative techniques, such as colectomy and excision, segmental colonic resection, hemicolectomy or subtotal colectomy, including laparoscopic procedures [2, 4, 5, 6, 8-11, 14]. While colectomy with excision of the tumor and laparoscopic approaches should be considered for uncomplicated preoperatively diagnosed lipomas, more extensive operations should be performed in patients with questionable diagnosis and acute clinical symptoms [14].

Symptomatic colonic lipomas are very rare, presenting with a variety of symptoms depending on their size and position, often leading to misdiagnosis. Since these benign tumors are frequently revealed by laparotomy and the definitive diagnosis is made on the basis of histopathological examination [1], we can conclude that extensive resections of the large intestine are justified in cases with acute clinical presentation.

## REFERENCES

- Bardaji M, Roset F, Camps R, Sant F, Fernandez-Layos MJ. Symptomatic colonic lipoma: differential diagnosis of large bowel tumors. *Int J Colorectal Dis.* 1998; 13:1-2.
- Rogy MA, Mirza D, Berlakovich G, Winkelbauer F, Rauhs R. Submucosal large-bowel lipomas-presentation and management. An 18 year study. *Eur J Surg.* 1991; 157:51-5.
- Bahadursingh AM, Robbins PL, Longo WE. Giant submucosal sigmoid colon lipoma. *Am J Surg.* 2003; 186:81-2.
- Namikawa T, Hokimoto N, Okabayashi T, Kumo M, Kobayashi M, Hanazaki K. Adult ileoileal intussusception induced by an ileal lipoma diagnosed preoperatively: report of a case and review of the literature. *Surg Today.* 2012; 42(7):686-92.
- Dultz LA, Ullery BW, Sun HH, Huston TL, Eachempati SR, Barie PS, et al. Ileocecal valve lipoma with refractory hemorrhage. *JSL.* 2009; 13(1):80-3.
- Meshikhes AW, Al Momen SA, Al Talaq FT, Al Jaroop AH. Adult intussusception caused by a lipoma in the small bowel: report of a case. *Surg Today.* 2005; 35:161-3.
- Khawaja F. Pedunculated lipoma of the colon. Risks of endoscopic removal. *South Med J.* 1987; 80:1176-9.

8. Chung YF, Ho YH, Nyam DC, Leong AF, Seow-Choen F. Management of colonic lipomas. Aust NZJ Surg. 1998; 68:133-5.
9. Chiba T, Suzuki S, Sato M, Tsukuhara M, Saito S, Inomata M, et al. A case of a lipoma in the colon complicated by intussusception. Eur J Gastroenterol Hepatol. 2002; 14:701-2.
10. Ryan J, Martin JE, Pollock DJ. Fatty tumours of the large intestine: a clinicopathological review of 13 cases. Br J Surg. 1989; 76:793-6.
11. Vecchio R, Ferrara M, Mosca F, Ignoto A, Latteri F. Lipomas of the large bowel. Eur J Surg. 1996; 162:915-9.
12. Lee ES, Lee KN, Choi KS, Lee HL, Jun DW, Lee OY, et al. Endoscopic treatment of a symptomatic ileal lipoma with recurrent ileocolic intussusception by using cap-assisted colonoscopy. Clin Endosc. 2013; 46(4):414-7.
13. Franc-Law JM, Begin LR, Vasilevsky CA, Gordon PH. The dramatic presentation of colonic lipomata: report of two cases and review of literature. Am Surg. 2001; 67:491-4.
14. Ghidirim G, Mishin I, Gutsu E, Gagauz I, Danch A, Russu S. Giant submucosal lipoma of the cecum: Report of a case and review of literature. Rom J Gastroenterol. 2005; 14:393-6.

## Петелькасти опструктивни липом илеоцекалне валвуле: приказ болесника

Берислав Векић, Растко Живић

Хируршка клиника, Клиничко-болнички центар „Др Драгиша Мишовић“ – Дедиње, Београд, Србија

### КРАТАК САДРЖАЈ

**Увод** Липоми дебелог црева су релативно чести, међутим, ретко доводе до акутне опструкције црева.

**Приказ болесника** Приказујемо случај 67-годишње жене с акутном опструкцијом црева узрокованом великим петелькастим липомом илеоцекалне валвуле. Болесница је примљена као хитан хируршки случај с клиничким и радиографским знацима илеуса танког црева. Начињена је десна хемиколектомија с примарном термино-латералном анастомозом. Патохистолошким прегледом потврђен је петелькасти бенигни липом илеоцекалне валвуле који је

узроковао увлачење илеума у цекум с последичном илеоколичном интусусцепцијом. Постоперациони ток је протекло без компликација, а болесница је била без симптома током једногодишњег периода клиничког праћења.

**Закључак** С обзиром на то да се ови бенигни тумори често откривају током операције и да се коначна дијагноза поставља тек патохистолошким прегледом, можемо закључити да су опсежне ресекције дебелог црева оправдане код болесника с акутном клиничком презентацијом.

**Кључне речи:** илеоцекални липом; акутна опструкција црева; операција дебелог црева; интусусцепција

Примљен • Received: 23/12/2013

Ревизија • Revision: 04/03/2014

Прихваћен • Accepted: 19/03/2014