

Dysfunctional Ectopic Thyroid Gland: A Case Report

Edita Stokić^{1,2}, Vladimir Kljajić^{1,3}, Stevan Idjuški^{1,4}, Damir Benc^{1,2}, Djordje Popović^{1,2}, Mladjan Protić^{1,5}, Veljko Crnobrnja^{1,6}

¹Faculty of Medicine, University of Novi Sad, Novi Sad, Serbia;

²Clinic for Endocrinology, Diabetes and Metabolic Disorders, Clinical Center of Vojvodina, Novi Sad, Serbia;

³Clinic for Otorhinolaryngology, Clinical Center of Vojvodina, Novi Sad, Serbia;

⁴Centre for Radiology, Clinical Center of Vojvodina, Novi Sad, Serbia;

⁵Clinic for Abdominal, Endocrine and Transplantation Surgery, Clinical Center of Vojvodina, Novi Sad, Serbia;

⁶Department for Nuclear Medicine, Clinical Center of Vojvodina, Novi Sad, Serbia

SUMMARY

Introduction Lingual thyroid gland is a rare anomaly of thyroid gland development, occurring more frequently in females. If it causes local symptomatology such as dysphagia, dysphonia or dyspnea it is diagnosed in childhood, however, if it is asymptomatic it is usually diagnosed in adulthood.

Case Outline We present a 23-year-old female patient in whom we diagnosed lingual thyroid gland coincidentally during diagnostic procedures of a concomitant disease. The application of ¹³¹I scintigraphy showed an oval field of intensive accumulation of radio markers in the zone of medial face line, around tongue base, with the absence of thyroid gland in its physiological position. Functional testing proved primary hypothyroidism and we started the application of substitution therapy. The application of levothyroxine resulted in reaching euthyroid state and the reduction of thyroid gland size.

Conclusion We present a very rare anomaly of the thyroid gland, and so far there have been no clear attitudes about further treatment. The general condition of the patient, age, the size of ectopic thyroid gland and the existence of local symptomatology or complications represent the factors that have influence on the choice of treatment method.

Keywords: ectopic thyroid gland; lingual thyroid gland; anomalies of thyroid gland

INTRODUCTION

As a consequence of disorders of embryogenesis during the passage of thyroid gland through the neck structures, an anomaly can occur in the form of ectopy. Thus, the thyroid gland can be localized in the neck zone, lingually, sublingually, prelaryngeally or it can rather be found at some less common localities such as the mediastinum, trachea, lungs, heart, breasts, pharynx, esophagus, duodenum, small intestines, adrenal gland, retroperitoneally or in other zones [1-7].

The finding of lingual thyroid gland is the most frequent disorder of this ectopy, and its incidence in the population ranges between 1:100000 and 1:300000 [1]. It is even 3-7 times more frequent in females [8]. After having conducted a retrospective study, Rahbar R. et al. [2] emphasize that lingual localization of thyroid gland in childhood represents a very rare disorder with the incidence of 1:100000. They state that this anomaly is asymptomatic over a long period, and that a coinciding illness or intensive growth and development at puberty lead to clinical manifestation due to some morphologic changes. However, due to the enlargement of ectopic thyroid gland abnormal patterns of breathing or swallowing can develop, and it is the moment when this disorder is most frequently diagnosed [9].

CASE REPORT

A 23-year-old female patient presented at the Emergency Centre of the Clinical Centre of Vojvodina in Novi Sad due to the pain in the left ear area. She felt first discomforts about 10 days prior to presentation, and besides pain she also noticed defective hearing in her left ear. She has been also feeling rather tired over the past several months. Previously to this event the patient underwent appendix surgery and had frequent pharyngitis as a child but no other illnesses. Her family history was uneventful except for paternal type 2 diabetes.

By physical examination of the neck, primarily palpation, thyroid gland enlargement in the lower third of the neck was not detected. Oropharyngoscopic examination findings were normal. Otomicroscopic examination of the left auditory canal revealed the presence of detritus matching mycoses. On the left side of the tongue root, indirect laryngoscopy verified the presence of a spherical, smooth change of dark pink-reddish color, elastic consistency, and clearly defined from the surrounding area (Figures 1 and 2). Based on otoscopic findings medication therapy with local antimycotics was advised.

Due to the diagnosed change in the tongue base root, CT of the head and neck was performed. In oropharynx, near the root of the tongue base and dorsally, CT scanner showed

Correspondence to:

Edita STOKIĆ
Clinic for Endocrinology, Diabetes
and Metabolic Disorders
Clinical Center of Vojvodina
Hajduk Veljkova 1, 21000 Novi Sad
Serbia
edith@sezampro.rs

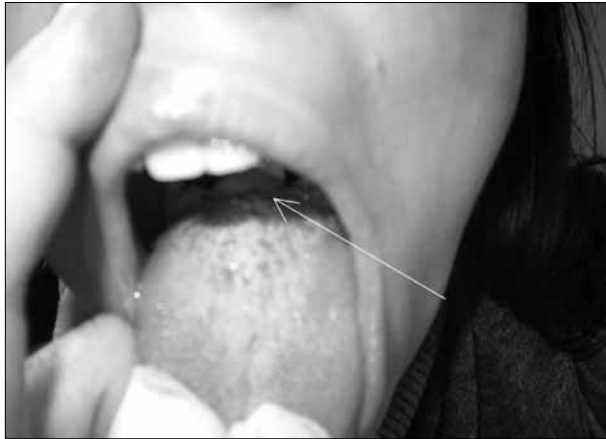

Figure 1. Rosy change of smooth surface with visible blood vessels. With the help of endoscope for indirect laryngoscopy it is not possible to present ectopic thyroid gland completely. A smooth rosy change is observed which completely fills the visual field of endoscope along with traces of blood vessels.

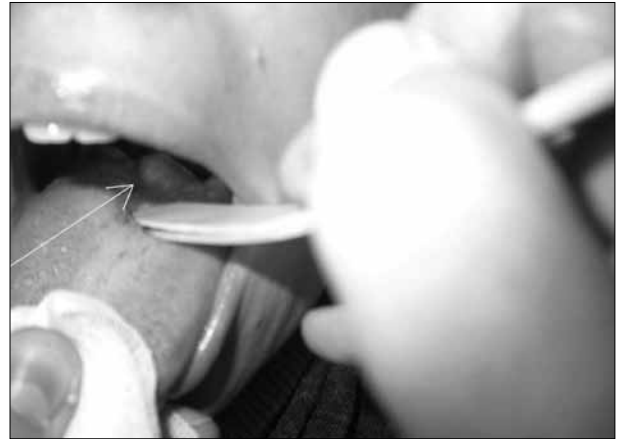

Figure 2. By the maneuver of tongue traction and pressure to the median and last third of the tongue, ectopic thyroid gland is completely presented. It is localized in the middle line and stretches to the left side. Its dimension is 2x2.5 cm; it is of rosy color, smooth surface, clearly demarcated from the surrounding tonsillar tissue of lingual tonsils.

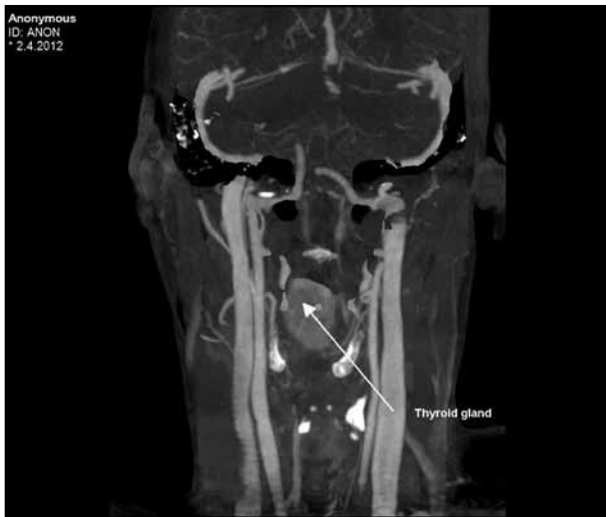

Figure 3. CT scan: a hyperdense solid nodular mass on the tongue base

the existence of a hyperdense clearly defined soft tissue change in size of 21x22x32 mm, and which was post-contrast well and homogenously enhanced and richly vascularized. It was also slightly pressed in the tongue root, stretched to the level of the epiglottis; also, it dorsally narrowed the lumen of the oropharynx. It was concluded that the change in the oropharynx could match the tissue of the thyroid gland in atypical position, having in mind the fact that the same was not found in the region of its otherwise physiological position (Figure 3).

The endocrinologist that was consulted at the time suggested scintigraphy of the thyroid gland and evaluation of its function. Thyroid gland scintigraphy by the application of ¹³¹I showed an oval area of intensive accumulation of radiopharmaceutic in the zone of the medial face line, around the tongue base. In the area of the anatomical localization of the thyroid gland there was a lack of functional tissue, thus we confirmed the diagnosis of ectopic localization of the thyroid gland (Figure 4). Testing of the thyroid gland function verified increased TSH (thyroid-stimulating hormone) level (11.02 mIU/l (normal range 0.35-4.94)) and normal concentration of T3 (triiodothy-

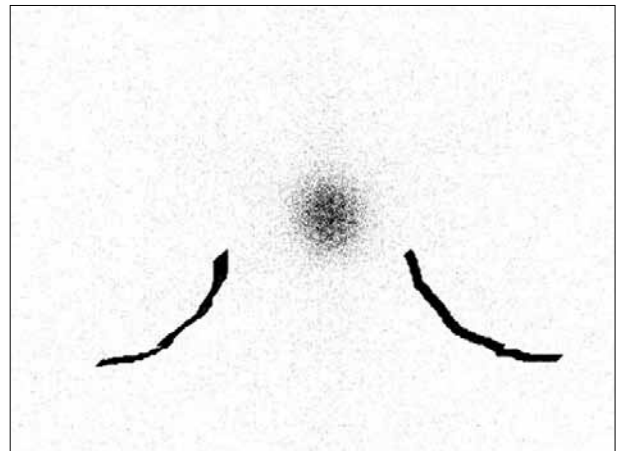


Figure 4. Scintigraphy of the thyroid gland by the application of ¹³¹I in the tongue base shows the acceptance of radio markers and the absence of accumulation in the area of physiological location of the thyroid gland

ronine) (1.7 nmol/l (normal range 1.0-2.7)) and T4 (thyroxine) (76 nmol/l (normal range 60-160)). Antithyroid peroxidase antibodies were negative. Other laboratory testings were within the referential values (Table 1). We started with substitution therapy administering levothyroxine with the aim of reaching euthyroid state.

Table 1. Results of conducted laboratory testing

Laboratory testing		Value
Complete blood count	Red blood cells (x10 ¹² /l)	4.49
	Hemoglobin (g/l)	131
	Hematocrit (%)	39.3
	White blood cells (x10 ⁹ /l)	6.3
	Platelets (x10 ⁹ /l)	210
Glucoregulation	Fasting and 2 hour after meal glycemia (mmol/l)	4.6...4.8
Thyroid gland function	Thyroxine (nmol/l)	69
	Triiodothyronine (nmol/l)	1.6
	Thyroid stimulating hormone (mIU/l)	11.02
	Antithyroid peroxidase antibodies (IU/ml)	<0.5

DISCUSSION

This case report is presented for several reasons. Our intention was to point out the possibility of the absence of symptomatology over a long period, as well as to underline some diagnostic and therapeutic dilemmas.

The existence of the lingual thyroid gland is a rare anomaly occurring due to damage in the embryological development of thyroid gland. It is clinically manifested as the existence of spherical mass in the tongue base zone. It is of smaller dimensions, but the size can range from several millimeters to several centimeters. The majority of patients with thyroid ectopy are asymptomatic, but in case it is of large dimensions it can lead to the development of local symptomatology manifesting in the form of dysphagia, dyspnea or dysphonia. If symptomatology is present, ectopic thyroid gland can be detected at an earlier age, while in symptomatic patients it is diagnosed in adulthood as a coincidental finding.

It is necessary to pay special attention to coincidental finding of ectopically placed thyroid gland on the tongue base because such placement can be mistaken for a tumor process. The physician practitioner who wishes to obtain pathohistological verification of a tumor process as soon as possible can decide on a biopsy of tumor change in local anesthesia. In that case, heavy bleeding can occur, which is difficult to control under the conditions of biopsy specimen taken under epimucous anesthesia. The patient who presented to the otorhinolaryngologist for examination complaining of earache, and in whom a tumefaction on the tongue root was detected, otherwise not placed there, always arises a suspicion of the existence of some malignant process of the tongue base. Reflexive otalgia develops in patients with advanced malignant tumors in the area of the larynx, tongue base, hypopharynx and oropharynx appearing as the consequence of a degree of affection of vagal fibers. When all elements are arranged in this way, it is primarily necessary to exclude a malignant disease of the tongue base. The palpatory finding of tumefaction on the tongue base was the finding which pointed out that it was not the case of malignant infiltrative tumor process. As for its consistency, the change differentially diagnostically could match hematologic diseases that can be found in the area of lingual tonsils, although the epithelial structure was different.

Although it can be asymptomatic over a long period, the lingual thyroid gland can be diagnosed as a coincidental finding during concurrently applied diagnostic procedures. Namely, contemporary techniques of visualization such as ultrasonography, computerized tomography and magnetic resonance are being increasingly applied. In our patient, the ectopic lingual thyroid gland was diagnosed as a coincidental finding during an ORL specialist examination and computerized tomography was performed due to the change on the tongue base. We pay special attention to the importance of the earliest possible diagnosis of this anomaly because in particular situations, such as coincidental diseases, heavy infections, traumas and pregnancy, can lead to diagnostic and therapeutic dilemmas if disorder of the thyroid gland is present. However, we must not neglect the fact that in our patient this anomaly

was diagnosed as late as when she was 23 years of age. It is to be expected that this patient underwent physician's examinations due to frequent pharyngitis in her childhood; nevertheless, this anomaly was not detected.

The basis of diagnostic procedures of ectopic thyroid gland is most certainly palpation of the neck by which no verification of thyroid gland existence is achieved. A definitive diagnosis is made by the application of Tc-99m, ¹³¹I or ¹²³I scintigraphy method. This is the most important diagnostic procedure which can detect the ectopic tissue of the thyroid gland. However, other radiological techniques such as Doppler ultrasonography, computerized tomography and magnetic resonance can also help in the evaluation of the localization of ectopic thyroid gland. Besides, chest X-ray can be of help, especially in the intrathoracic localization of the thyroid gland [10].

In relation to functional disorders, even in 70% patients with the lingual thyroid gland we can verify a decreased function, which requires the administration of adequate substitution therapy [11]. In our patient we established primary hypothyroidism and introduced substitution therapy with 50 µg of levothyroxine, which resulted in achievement of euthyroid state. In patients with an enlarged thyroid gland who have increased TSH concentration, therapy with levothyroxine can produce favorable effects. During this therapy, size reduction of the thyroid gland can be recorded. We noted decreased size of the thyroid gland during a check-up examination after the patient reached euthyroid state.

From the aspect of further optimal therapeutic treatment there are no clear standpoints, especially having in mind that we present a rare disease. If the lingual thyroid gland is without any symptomatology with regard to the localization and with no functional disorders, there is no need for further treatment [10]. It should not be neglected that the ectopic thyroid gland can be accompanied by all diseases like in a normally localized thyroid gland. However, the literature also reported description of possible malignant transformation; therefore some authors advise total thyroidectomy to be performed [12, 13].

In cases that are completely asymptomatic and euthyroid, it is necessary to further observe the patient in order to exclude potential enlargement or the occurrence of complications (ulcerations, bleeding, cystic degeneration or the development of malignancy).

The existence of ectopic lingual thyroid gland is rare. If it is asymptomatic, it is most frequently diagnosed in adulthood, usually like a coincidental finding during the application of contemporary diagnostic procedures. The finding of ectopically placed thyroid gland on the tongue base is possible to be mistaken for a tumor process, therefore wishing to obtain pathohistological verification it is possible to indicate the biopsy of this change. That could be followed by numerous complications. Thyroid gland scintigraphy plays an important role in passing the final diagnosis.

The factors that can have an influence upon assuming an attitude about the selection of treatment are the following: general condition of the patient, age, the size of ectopic thyroid gland and existence of local symptomatology or complications.

REFERENCES

1. Toso A, Colombani F, Averono G, Aluffi P, Pia F. Lingual thyroid causing dysphagia and dyspnoea. Case reports and review of the literature. *Acta Otorhinolaryngol Ital.* 2009; 29(4):213-7.
2. Pelizzo MR, Torresan F, Grassetto G, Briani G, Marzola MC, Rubello D. Imaging identifies submandibular ectopic thyroid tissue. *Clin Nucl Med.* 2011; 36(8):728-30.
3. Cassol CA, Noria D, Asa SL. Ectopic thyroid tissue within the gallbladder: case report and brief review of the literature. *Endocr Pathol.* 2010; 21:263-5.
4. Ghanem N, Bley T, Altheoefer C, Högerle S, Langer M. Ectopic thyroid gland in the porta hepatis and lingua. *Thyroid.* 2003; 13:503-7.
5. Babazade F, Mortazavi H, Jalalian H, Shahvali E. Thyroid tissue as a submandibular mass: a case report. *J Oral Sci.* 2009; 51:655-7.
6. Mysorekar VV, Dandekar CP, Sreevathsa MR. Ectopic thyroid tissue in the parotid salivary gland. *Singapore Med J.* 2004; 45:437-8.
7. Kutz M, Vila JJ, Urman JM, Garaigorta M, Guinduláin E, Tarifa A, et al. Ectopic retroperitoneal thyroid gland. *Gastroenterol Hepatol.* 2012; 35(6):400-3.
8. Shah BC, Ravichand CS, Juluri S, Agarwal A, Pramesh CS, Mistry RC. Ectopic thyroid cancer. *Ann Thorac Cardiovasc Surg.* 2007; 13:122-4.
9. Rahbar R, Yoon MJ, Connolly LP, Robson CD, Vargas SO, McGill TJ, et al. Lingual thyroid in children: a rare clinical entity. *Laryngoscope.* 2008; 118(7):1174-9.
10. Noussios G, Anagnostis P, Goulis DG, Lappas D, Natsis K. Ectopic thyroid tissue: anatomical, clinical, and surgical implications of a rare entity. *Eur J Endocrinol.* 2011; 165(3):375-82.
11. Singhal P, Sharma KR, Singhal A. J Lingual thyroid in children. *Indian Soc Pedod Prev Dent.* 2011; 29(3):270-2.
12. Hari CK, Kumar M, Abo-Khatwa MM, Adams-Williams J, Zeitoun H. Follicular variant of papillary carcinoma arising from lingual thyroid. *Ear Nose Throat J.* 2009; 88(6):E7.
13. Kennedy TL, Riefkohl WL. Lingual thyroid carcinoma with nodal metastasis. *Laryngoscope.* 2007; 117(11):1969-73.

Дисфункционална ектопична штитаста жлезда – приказ болесника

Едита Стокић^{1,2}, Владимир Кљајић^{1,3}, Стеван Иђушки^{1,4}, Дамир Бенц^{1,2}, Ђорђе Поповић^{1,2}, Млађан Протић^{1,5}, Вељко Црнобрња^{1,6}

¹Медицински факултет, Универзитет у Новом Саду, Нови Сад, Србија;

²Клиника за ендокринологију, дијабетес и болести метаболизма, Клинички центар Војводине, Нови Сад, Србија;

³Клиника за болести ува, грла и носа, Клинички центар Војводине, Нови Сад, Србија;

⁴Центар за радиологију, Клинички центар Војводине, Нови Сад, Србија;

⁵Клиника за абдоминалну, ендокрину и трансплантациону хирургију, Клинички центар Војводине, Нови Сад, Србија;

⁶Одељење за нуклеарну медицину, Клинички центар Војводине, Нови Сад, Србија

КРАТАК САДРЖАЈ

Увод Језична штитаста жлезда је ретка аномалија у развоју штитасте жлезде која се чешће јавља код особа женског пола. Уколико изазива локалне сметње, као што су дисфагија, дисфонија или диспнеја, открива се у детињству, али уколико је асимптоматска, обично се дијагностикује у одраслом добу.

Приказ болесника Приказали смо двадесеттворогодишњу болесницу код које је језична штитаста жлезда откривена случајно, током дијагностичких процедура придружене болести. Сцинтиграфском методом помоћу радиоактивног јода (¹³¹I) приказано је овално поље интензивне акумулације радиофармака у пределу средње фацијалне линије,

око базе језика, уз изостанак штитасте жлезде у свом уобичајеном анатомском положају. Функционално испитивање је указало на примарни хипотиреоидизам, те је започета супституциона терапија. Примена левотироксина је довела до еутиреоидног стања болеснице и смањења величине штитасте жлезде.

Закључак Приказана је веома ретка аномалија штитасте жлезде о чијем даљем лечењу досад није било јасних ставова. Опште стање болесника, величина ектопичне штитасте жлезде и постојање локалне симптоматологије или компликација јесу чиниоци који утичу на избор начина лечења.

Кључне речи: ектопична штитаста жлезда; језична штитаста жлезда; аномалије штитасте жлезде