

Granulomatosis with Polyangitis (Wegener's) and Central Nervous System Involvement: Case Report

Aleksandra Tomić Lučić¹, Mirjana Veselinović¹, Suzana Pantović², Dejan Petrović³,
Sandra Živanović², Jasmina Milovanović²

¹Department of Rheumatology, Internal Clinic, Clinical Center of Kragujevac, Kragujevac, Serbia;

²University of Kragujevac, Faculty of Medical Sciences, Kragujevac, Serbia;

³Clinic for Nephrology and Urology, Clinical Center of Kragujevac, Kragujevac, Serbia

SUMMARY

Introduction Granulomatosis with polyangitis (Wegener's) is an antineutrophil cytoplasmic antibody (PR3-ANCA)-associated vasculitis, which commonly involves the upper and lower respiratory tracts and kidneys. Central nervous system involvement is reported in less than 11%, and rarely present at onset.

Case Outline We report the case of a 41-year-old male patient with a high disease activity, large organ involvement, as well as central nervous system manifestations presented at onset. Treatment with intravenous pulse methylprednisolone, followed by the pulsed doses of cyclophosphamide was induced. After 6 months of cyclophosphamide pulse therapy a remission was achieved. Next, azathioprine was used for maintenance during the next 18 months. There were no disease flares during 24-month follow-up.

Conclusion Granulomatosis with polyangitis (Wegener's) with large organ involvement, affecting the central nervous system structures require a rapid diagnosis and intensive medication treatment in order to prevent or reduce irreversible damage. Our experience confirms the findings reported in the literature that the severe forms of the disease are associated with increased probability of achieving remission, which reflects increased responsiveness of such patients to immunosuppressant therapy.

Keywords: granulomatosis polyangitis (Wegener's); central nervous system; treatment; outcome

INTRODUCTION

Granulomatosis with polyangitis (Wegener's) (GPW) is an antineutrophil cytoplasmic antibody (PR3-ANCA)-associated granulomatous vasculitis of small vessels. This vasculitis involves mainly the upper and lower respiratory tracts, lung tissue and kidneys, although GPW may affect any organ. Whereas the peripheral nervous system is often involved in GPW, central nervous system (CNS) manifestations are reported in less than 11%, and are rarely present at disease onset of the disease [1, 2]. We report the case of a patient with involvement of the upper and lower respiratory tract and kidneys, as well as CNS manifestations of GPW presented at the onset of the disease. Based on this case and a review of the literature, we discuss the pathogenic mechanisms, clinical features, treatment, and outcome.

CASE REPORT

A 41-year-old male patient was admitted at the Department of Rheumatology because of fever, joint pains, epistaxis, rhinorrhea, cough and weight loss of 4 kg per month. The symptoms started a month before hospitalization with no improvement after antibiotic treatment.

On admission the patient had fever (39°C), without signs of cutaneous vasculitis. There was vesicular breath sound, with a few late inspiratory crackles over the posterior bases

of the lungs, with normal heart sounds. Oxygen saturation by pulse oxymetry was 94%, and a partial pressure of oxygen (PO₂) about 9.3 kPa. Arthralgia of hand joints and limited and painful movement of both shoulders were present. High blood pressure (160/100 mmHg) occurred later during hospitalization and required antihypertensive treatment.

Blood tests showed elevated erythrocyte sedimentation rate 87 mm/h, C-reactive protein levels 167 mg/L and fibrinogen 6.2, with higher levels of white blood cells $11.9 \times 10^9/l$ and platelets $771 \times 10^9/l$, moderate normocytic anemia hemoglobin 108 g/l, red blood cells $3.4 \times 10^{12}/l$, higher levels of transaminases (AST 84, ALT 183, GGT 169, ALP 210, LDH 442 U/l), increased levels of CK-MB 17.5 U/l and troponine I 0.377 µg/l, lower levels of albumin 25 g/l and normal ranges of total proteins and blood nitrogen materials. There were more than 10 RBC/ml in urine sediment (infection was excluded). Creatinine clearance was within the normal range, but there were high levels of daily proteinuria 1.75 g/24 hours. Immunological analysis showed increased levels of PR3-ANCA 196 U/ml and Rheumatoid Factor 170 U/ml. The bacterial culture of the throat, nasal discharge, blood and urine were sterile.

MSCT of the chest showed bilateral, nodular infiltrates of the lungs, 10 mm in size with central cavitations and without signs of secondary infection; X-ray of the paranasal sinuses showed a reduced transparency in the area of the maxillary, ethmoidal and frontal sinuses,

Correspondence to:

Aleksandra TOMIĆ LUČIĆ
Internal Clinic
Department of Rheumatology
Clinical Centre of Kragujevac
Zmaj Jovina 30, 34000 Kragujevac
Serbia
sanlusa@ptt.rs

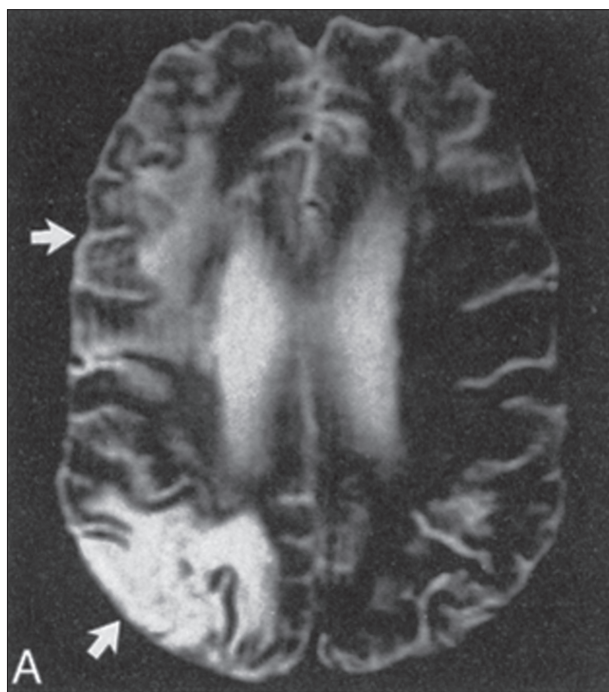


Figure 1. Axial spin-echo MR image of endocranium (3000/90 images) shows T2W/FLAIR hyperintense signal changes (infarcts) in the right cortical gray matter and subcortical white matter (middle cerebral artery distribution, upper arrow; middle cerebral artery/posterior cerebral artery watershed distribution, lower arrow).

which corresponded to chronic sinusitis. Sinus ethmoidal biopsy was performed at the ORL Department of the Clinical Center Kragujevac. Histopathology examination was performed at the Department for Pathology of the same Clinical Center and Faculty of Medical Sciences of Kragujevac. It showed vasculitis of small arteries and veins with fibrinoid necrosis surrounded by histiocytes, and granulomas with central necrosis, plasma cells and giant cells infiltration. This corresponded to the histological lesions of GPW.

During hospitalization, the patient complained of severe headaches and impaired vision in the form of transient diplopia. Neurological examination, including the cranial nerve and motor system examination, deep tendon reflexes, coordination and gait, as well as sensory examination was normal. Ophthalmic examination was also normal. Electrophysiological studies, such as electroencephalography and evoked potentials did not detect changes associated with specific clinical findings. MR imaging of endocranium was performed and it showed two T2W hyperintense signal changes (infarcts) in the right cortical gray matter and subcortical white matter (Figure 1). Infarcts were localized in the middle cerebral artery distribution, and middle cerebral artery/posterior cerebral artery watershed distribution. These cerebral infarctions were consistent with CNS vasculitis.

ECG performed on admission was normal, except for mild sinus tachycardia. Transthoracic echocardiography showed only a mild hypokinesia of the septum and anterior wall. Ejection fraction was 55%.

The diagnosis of GPW was based on the definition and classification criteria of Wegener's granulomatosis accord-

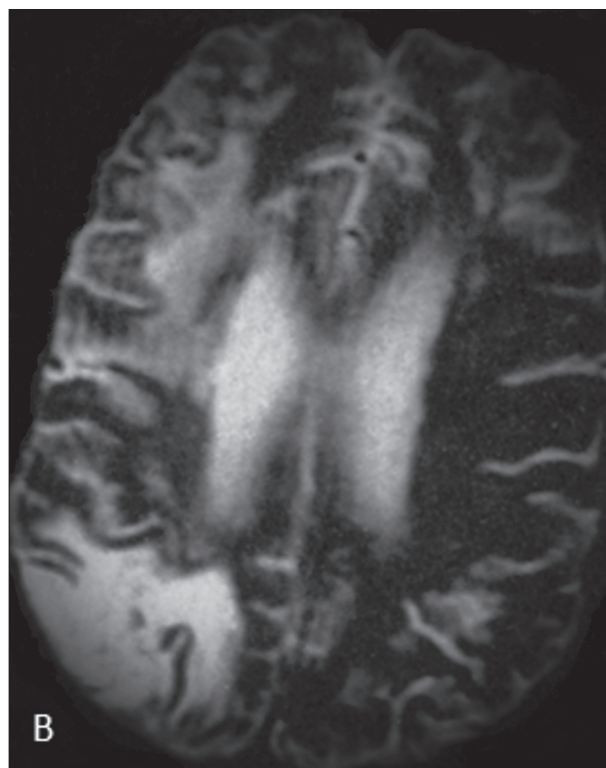


Figure 2. Control axial spin-echo MR image of endocranium shows two hyperintense signal changes in the right cortical gray matter and subcortical white matter (old infarcts). There were no new cerebrovascular accidents.

ing to the revised Chapel Hill Consensus (CHC) [3]. The patient had inflammatory process in the paranasal cavities, granulomatous infiltration of the lungs, renal lesion - hematuria, proteinuria and arterial hypertension, biopsy findings from a sample of the ethmoidal sinus and an increased titer of PR3-ANCA. There were also present CNS lesions in the form of vasculitis. The disease extent index (DEI) at the onset was 11 (E, H, L, K, C, A, B), which corresponded with a large organ involvement [4]. Vasculitis disease activity at the onset was 35 according to the Birmingham Vasculitis Activity Score (BVAS-1) [4].

Treatment with intravenous pulse methylprednisolone (0.5 g/day for 3 consecutive days), followed by pulsed doses of (intravenous) cyclophosphamide (15 mg/kg) were induced. After intravenous pulses of methylprednisolone, oral prednisolone (20 mg/day) was additionally used, as a part of remission induction therapy. Headaches and impaired vision were stopped soon after the induction of pulse doses of steroids. Increased levels of cardiac enzymes and troponine were also normalized. Intravenous pulse cyclophosphamide every 2 weeks were performed for the first 3 pulses, followed by infusions every 3 weeks for the next 6 pulses. After 6 months of induction therapy, remission was achieved and control MSCT of the chest showed a complete regression of previous infiltrates. Renal function normalized, with withdrawal of hematuria and proteinuria and normal arterial tension. Severe headaches and transient diplopia were only neurological symptoms and did not occur again during follow-up. On control MR imaging of the endocranium there were no new cerebrovascular accidents (Figure 2). Azathioprine in doses of 2 mg/kg/day

was used for maintenance of remission during the next 18 months. The glucocorticoid dose was tapered to a maintenance dose of 10 mg/day during remission. After remission was achieved there were no flares within 24 months of follow-up. Permanent organ damage scored by vasculitis damage index (VDI) after 24 months of follow-up was 1 [5].

DISCUSSION

Granulomatosis with polyangiitis (Wegener's) is one of ANCA-associated vasculitides and has a predilection for the upper and lower respiratory tracts and kidneys. Annual incidence of ANCA-associated vasculitides is estimated at approximately 10-20/million with a peak age of onset in persons aged 65 to 74 years [6].

The pathogenesis of GPW is not fully understood. It has been suggested that there is an association between infections with fimbriated bacteria (which include several types of Gram-negative bacteria) that can initiate the auto-immune process [7]. Recent data emphasize the involvement of lysosomal associated membrane protein 2 (LAMP-2) [7]. Rising PR3-ANCA (C-ANCA) titers may correlate with disease activity in approximately two-thirds of patients [8]. However, the relationship is unreliable; thus, negative PR3-ANCA results do not necessarily exclude the possibility of relapse [8]. There are literature data which show that severe CNS manifestations could represent a clinical hallmark of patients with generalized GPW who are consistently negative for PR3-ANCA [8].

GPW has a spectrum of clinical presentations and may be divided broadly into a limited or severe disease. Individuals with limited GPW present clinical findings largely isolated to the upper and lower respiratory tracts and are generally not considered to have organ- or life-threatening disease. Persons with severe disease present significant multisystem manifestations that may involve the lungs, kidneys, and other organs, in addition to the respiratory tract [1].

In this case report we described a patient with severe GPW and CNS involvement. Cerebral vasculitis was present at disease onset, suggesting, as reported in the literature, that although early systemic forms of GPW could hide CNS involvement, intensive treatment can be required [1]. CNS involvement is an uncommon manifestation of GPW, reported in 7%-11% of patients [2]. It is rarely present at onset, and occurs 5-18 years after GPW diagnosis in most patients [1, 2]. Three major mechanisms have been incriminated as causing CNS disease in GPW: contiguous invasion of granuloma from extracranial sites, remote intracranial granuloma, and CNS vasculitis. Granulomatous manifestations originating from the ear-nose-throat tract and affecting CNS structures are most common CNS manifestations [9]. MR imaging is very sensitive for CNS vasculitis and typically shows multiple subcortical infarctions, although substantial variation in the number, size, and location of lesions may occur in this condition. The most common are supratentorial infarctions in the

cortical and subcortical regions. Although most of the lesions revealed by MR imaging are infarctions, hemorrhagic lesions also occur: intraparenchymal hemorrhages, as well as subarachnoid hemorrhages (SAH) [10]. The literature has also reported a few cases with chronic hypertrophic pachymeningitis [2, 8].

Vasculitis disease activity was scored according to the Birmingham Vasculitis Activity Score (BVAS-1) [4]. BVAS-1 scores nine organ systems for new or worse vasculitis findings, and with maximum total BVAS-1 score of 63. According to the BVAS-1 score of 35 points, our patient had a high disease activity at onset [4]. Organ involvement was defined according to the disease extent index (DEI) which records vasculitis activity in 10 organ systems, with maximal score of 20 and one point more added for constitutional symptoms [4]. DEI of this patient was 11 (E, H, L, K, C, A, B), which corresponds with large organ involvement. Permanent organ damage was scored by VDI, which gives a cumulative record of damage that must have been present for at least 3 months. Eleven organ based systems are recorded with maximum score of 64 [5]. VDI of this patient after 24 months of follow-up was 1, which corresponds to small permanent organ damage.

As previously noted in the literature, early diagnosis as well as intensive therapeutic intervention is essential to optimize patient's survival and prevent or reduce potential damage [11]. Treatment of GPW can be broken down into 4 stages: diagnosis; remission induction; remission maintenance and long-term follow-up with early recognition and treatment of relapses. According to the EULAR recommendations for the management of primary small and medium vessel vasculitis, when a rapid effect is needed, intravenous pulsed methylprednisolone may be used in addition to oral prednisolone as a part of remission induction therapy [12].

The combination of steroids and pulse cyclophosphamide (CYC) is recommended for the induction treatment of severe GPW. A meta-analysis of the randomized controlled trials concluded that pulsed cyclophosphamide was more likely to result in remission than continuous oral therapy, and with a lower risk of side effects [12, 13]. However, pulsed therapy may be associated with a higher risk of relapse [12, 13]. An alternative option for induction treatment is the use of the anti-CD20 antibody, rituximab [12, 13]. Methotrexate, azathioprine and mycophenolate mofetil are recommended as alternatives to CYC once remission is achieved. Their use can also reduce the need for a long-term glucocorticoid therapy [14]. The remission rate in GPW ranges from 30-93%, depending on the definition of remission and the remission induction therapy used [15]. The definition of remission varied from commencement of clinical improvement, to complete absence of disease manifestations for at least 6 months [14]. In this case report the patient had severe GPW with high disease activity and large organ involvement, affecting the CNS structures at onset. Fast diagnostic work-up and intensive therapeutic intervention induced remission, as defined by complete absence of disease manifestations for 6 months, and reduced potential damage. It confirms previous ob-

servations that the severe forms of GPW, defined by BVAS higher than 23, are associated with increased likelihood of achieving remission [15]. This finding may reflect increased responsiveness of severe disease to immunosuppression.

REFERENCES

1. Tumiati B, Zuccoli G, Pavone L, Buzio C. ENT Wegener's granulomatosis can hide severe central nervous system involvement. *Clin Rheumatol*. 2005; 24(3):290-3.
2. Seror R, Mahr A, Ramanoelina J, Pagnoux C, Cohen P, Guillevin L. Central nervous system involvement in Wegener granulomatosis. *Medicine (Baltimore)*. 2006; 85(1):54-65.
3. Jennette JC, Falk RJ, Bacon PA, Basu N, Cid MC, Ferrario F, et al. 2012 revised International Chapel Hill Consensus Conference Nomenclature of Vasculitides. *Arthritis Rheum*. 2013; 65(1):1-11.
4. Bacon PA, Moots R, Exley A, Luqmani R, Rasmussen N. Vital assessment of vasculitis. *Clin Exp Rheumatol*. 1995; 13:75-8.
5. Exley AR, Bacon PA, Luqmani R.A, Kitas GD, Gordon C, Savage COS, et al. Development and initial validation of the Vasculitis Damage Index for the standardized clinical assessment of damage in the systemic vasculitides. *Arthritis Rheum*. 1997; 40:371-80.
6. Ntatsaki E, Watts RA, Scott DG. Epidemiology of ANCA-associated vasculitis. *Rheum Dis Clin North Am*. 2010; 36(3):447-61.
7. Kain R, Exner M, Brandes R, Ziehermayr R, Cunningham D, Alderson CA, et al. Molecular mimicry in pauci-immune focal necrotizing glomerulonephritis. *Nat Med*. 2008; 14:1088-96.
8. Reinhold-Keller E, de Groot K, Holl-Ulrich K, Arlt AC, Heller M, Feller AC, et al. Severe CNS manifestations as the clinical hallmark in generalized Wegener's granulomatosis consistently negative for antineutrophil cytoplasmic antibodies (ANCA). A report of 3 cases and a review of the literature. *Clin Exp Rheumatol*. 2001; 19(5):541-9.
9. Holle JU, Gross WL. Neurological involvement in Wegener's granulomatosis. *Curr Opin Rheumatol*. 2011; 23(1):7-11.
10. Pomper MG, Miller TJ, Stone JH, Tidmore WC, Hellmann DB. CNS vasculitis in autoimmune disease: MR imaging findings and correlation with angiography. *AJNR Am J Neuroradiol*. 1999; 20(1):75-85.
11. Lee R, D'Cruz D. Novel therapies for anti-neutrophil cytoplasmic antibody-associated vasculitis. *Drugs*. 2008; 68:747-70.
12. C Mukhtyar, Guillevin L, Cid MC, Dasgupta B, de Groot K, Gross W, Hauser T, et al. EULAR recommendations for the management of primary small and medium vessel vasculitis. *Ann Rheum Dis*. 2009; 68:310-7.
13. Berlit P. Diagnosis and treatment of cerebral vasculitis. *Ther Adv Neurol Disord*. 2010; 3(1):29-42.
14. Rihova Z, Jancova E, Merta M, Zabka J, Rysava R, Bartunkova J, et al. Daily oral versus pulse intravenous cyclophosphamide in the therapy of ANCA-associated vasculitis – preliminary single center experience. *Prague Med Rep*. 2004; 105:64-8.
15. Mukhtyar C, Flossmann O, Hellmich B, Bacon P, Cid M, Cohen-Tervaert JW, et al. Outcomes from studies of antineutrophil cytoplasm antibody associated vasculitis: a systematic review by the European League Against Rheumatism systemic vasculitis task force. *Ann Rheum Dis*. 2008; 67:1004-10.

ACKNOWLEDGMENT

We are grateful to Dr. Andjelka Lukić from the Department of Radiology of the Clinical Center of Kragujevac for help in the interpretation of MR images of the endocranium.

Грануломатоза с полиангитисом (Вегенерова) са захватањем централног нервног система – приказ болесника

Александра Томић Лучић¹, Мирјана Веселиновић¹, Сузана Пантовић², Дејан Петровић³, Сандра Живановић², Јасмина Миловановић²

¹Одељење за реуматологију, Клиника за интерну медицину, Клинички центар Крагујевац, Крагујевац, Србија;

²Универзитет у Крагујевцу, Факултет медицинских наука, Крагујевац, Србија;

³Клиника за нефрологију и урологију, Клинички центар, Крагујевац, Србија

КРАТАК САДРЖАЈ

Увод Грануломатоза с полиангитисом (Вегенерова) је PR3-ANCA позитиван васкулитис који обично захвата горњи и доњи дисајни тракт и бубреге. Захватање централног нервног система (ЦНС) се јавља у мање од 11% случајева и веома је ретко на почетку болести.

Приказ болесника У овом раду је приказан болесник стар 41 годину са широко распрострањеним и високо активним обликом болести од самог почетка и манифестацијама од стране ЦНС. Започето је лечење интравенским пулсним дозама метилпреднизолона и пулсним дозама циклофосфамида. Након шест месеци лечења пулсним дозама циклофосфамида постигнута је ремисија. После тога је следећих 18 месеци настављена терапија одржавања азатиоприном.

Није било реактивације болести током 24 месеца клиничког праћења.

Закључак Код болесника с грануломатозом и полиангитисом (Вегенеровом) који имају широко распрострањен облик болести, уз захватање ЦНС, неопходно је урадити брзу дијагностику и применити интензивно медикаментно лечење, како би се спречила или смањила неповратна оштећења. Наше искуство потврђује налазе објављене у литератури који кажу да је код болесника с тешким обликом обољења већа вероватноћа достизања ремисије, што указује на њихову повећану осетљивост на имunosупресивну терапију.

Кључне речи: грануломатоза с полиангитисом (Вегенерова); централни нервни систем; лечење; исход

Примљен • Received: 24/01/2014

Прихваћен • Accepted: 31/03/2014